

Comparative efficacy between surgical intervention, organophosphorus and ivermectin against humpsore (Stephanofilariasis) in cattle

M.Z.U. Ibrahim¹, M.A. Hashim², M.A. Hossain³, I. Al-Sultan⁴

¹ Doctor, Department of Surgery & Obstetrics, Faculty of Veterinary Science, Bangladesh Agricultural University, Mymensingh 2202, Bangladesh, ^{2&3} Professor, Department of Surgery and Obstetrics, Faculty of Veterinary Science, Bangladesh Agricultural University, Mymensingh 2202, Bangladesh, ^{2&4} Faculty of Veterinary Medicine, University Malaysia Kelantan
mirza_sarah1959@yahoo.com

Article Info

Received: 20.09.2013
Accepted: 16.10.2013
Published online: 01.11.2013

ABSTRACT

The experiment was carried out in 40 cattle to investigate the comparative efficacy of surgical intervention, using organophosphorus (Neguvon^R) and ivermectin against skin lesions due to Stephanofilariasis. Cattle of 1.5 to 6 years of age irrespective of sex having diagnosed skin lesions (Stephanofilariasis) were used in this experiment. Selected cattle were divided into four equal groups (group A, B, C and D): each group consisted of 10 cattle. Group A was treated by surgical excision of affected skin lesion. Animals of group B was treated with organophosphorus, Trichlorophon (Neguvon^R Sapco, Unichem, Bangladesh) ointment applied topically. Group C treated with Ivermectin (A-mectin, The ACME Lab. Ltd, Bangladesh) was administered subcutaneously @ 0.2 mg/kg body weight and repeated after 21 days at same dose. Group D kept as control Group. Cattle treated surgically were completely cured within 15-20 days in all cases. The rate of healing of lesions was rapid compare to organophosphorus and ivermectin treated groups and success of healing was 100%, whereas animals treated with organophosphorus ointment cured partially after 45 days of treatment and success of healing was 60% and those treated with ivermectin also cured partially in 45 days of treatment and the success of healing was 70%. Surgical excision was more effective in comparison to other treatments in respect to time required for healing, presence of exudates, alopecia and recurrence of infection which was shown by histopathologically as the restoration of surrounding hair follicle and increased production of new capillaries around the scar tissue at the newly cured area. Also, it was evident that the treatment with ivermectin was more effective than organophosphorus application in success of healing. It is suggested that surgical excision of the lesions produced by Stephanofilariasis may be used as an alternative treatment method in cattle.

Keywords: Excision, humpsore, Neguvon, Ivermectin, Stephanofilariasis, skin lesions

1. Introduction

'Humpsore' is a chronic granulomatous and ulcerative dermatitis located usually, on or near the region of hump of zebu cattle and is caused by a filarid parasite, *Stephanofilaria assamensis*. Clinical experience suggested that humpsore or stephanofilariasis is one of the important diseases cause serious leather defect. The disease is prevalent and wide spread in Bangladesh, 2.5% of the cattle population being affected. Humpsore is prevalent almost in all seasons of the year but aggravated in the summer and rainy season due to high temperature and high humidity which favors tremendous growth of fly vectors (Baki, 1995). The disease is prevalent in 9.5% of the adult cattle in low lying areas in Bangladesh but not reported in hilly areas. The disease is said to cause gradual deterioration of health, impaired work performances, diminished milk production and quality of hides. The affected animals remain restless due to irritation at the sores. Flies (*Musca conducens*, *M.ventrosa* and *Haematobia exigua*) are responsible for transmission of the disease. The highest (45%) incidence of *S. assamensis* larvae was recorded in *M.pattoni* in August and the lowest (16%) in December (Phukan et al., 2005). Skin infections are very common in cattle. The skin infections of cattle are self limiting and resolve on their own, but many others require treatment (Stulberg and Penord, 2002). As the disease is located mainly on or near the region of the hump and neck, it causes extensive damage to the skin. The value of the animals also reduced due to the ugly looking lesion all together accounts for huge economic loss. So far, no effective treatment and control measures could yet be adopted against the disease. This study was carried out with the following objectives: 1.To evaluate the efficacy of surgical intervention for the treatment of stephanofilariasis. 2. To compare the effectiveness of the surgical intervention to that of the organophosphorus and Ivermectin against Stephanofilariasis.

2. Materials and Methods

The work on comparative efficacy of various treatment regimens at clinical cases of Stephanofilariasis in cattle started on November 2009 till May 2010. A total of 40 cases of Stephanofilariasis were diagnosed and treated during this period. Areas selected for this research were confined within Mymensingh and Feni Districts of Bangladesh.

2.1 Demographic variables: Age, breed, sex, physical condition and hair coat were recorded. A total of 40 (18 Female and 22 Male) Cross bred and Zebu cattle (*Bos indicus*), age ranged between 1.5-6 years and having a lesion of Stephanofilariasis was selected for this experiment. The lesions of Stephanofilariasis were tentatively diagnosed by taking history and characteristic clinical signs.

2.2 Sample collection: A total of twelve skin scraping (3 from each group) was collected from different areas in sterile containers and aseptic technique was adopted for parasitological study. Among 12 samples six were collected from female with clinical signs and 6 were collected from male. Twelve biopsies (3 from each group) of skin from stephanofilarial lesions were collected before treatment for histopathology. Similarly, 12 biopsies of skin were collected after treatment with a view to study restoration of normal tissues in the humpsore areas and evaluate the efficiency of the treatment. Tissue biopsies were fixed in 10% neutral formalin solution processed under normal procedures and

embedded in paraffin. The tissue sections were cut at 5-6 micrometer and stained with Haematoxylin and Eosin for microscopy examination.

2.3 Diagnosis of Stephanofilariasis: The cases were diagnosed on the basis of clinical history, clinical signs and histopathological examination of skin section for presence of Stephanofilarial larvae and eggs. The clinical cases were confirmed as Stephanofilarial sore by the examination of skin scrapings in a standard procedure and histopathological examination.

2.4 Experimental design: The affected animals (n=40) were randomly allocated into 4 groups and were treated with surgical intervention and different drugs. The efficacies of treatment were assessed on the basis of skin healing, time of further introduction of affection and normal posture of the animal.

2.4.1 Group A: In this group the lesions of Stephanofilariasis were surgically excised. The range of skin excision was 3-10 cm, 6 female and 4 male cattle were subjected to this operation. The animals were closely monitored and kept overnight fasting. Surgery was performed under sedation with 0.1mg/kg xylazine hydrochloride (Rompun, 20 mg/ml, Bayer) and local infiltration with 2% lidocaine hydrochloride (Jasocaine, Jayson, BD Ltd). Routine scrubbed procedure and painting with povidone iodine was also performed before surgery. Procaine penicillin with streptomycin sulfate (SP Vet, Inj. 2.5 gm vial, ACME, Bangladesh) was given intramuscularly preoperatively and also postoperatively for 7 days at normal dose rate.

2.4.1.1 Technique of operation: The animals were taken in a cool shaded place and restrained on lateral recumbency. At first, the skin which part is to be removed was crushed with curved artery forceps from both sides before resection. A simple interrupted mattress sutures were given by nylon just beneath the crushing line with a view to control hemorrhage. Then the affected skin was cut down with surgical blades apart the crushing line. The area was soaked with Tinctur of iodine. The postoperative care included daily dressing of the skin wound with 0.5% chlorhexidine gluconate (Hexisol, ACI Ltd, Bangladesh) till healing. Oil of turpentine was also applied around the wound as fly repellent. Pheniramine maleate (Hista-Vet, ACI, Ltd. Bangladesh @0.8 mg/kg body weight was also administered. The skin sutures were removed after 10 days when healing occurred.

2.4.2 Group B: In this group 10 Stephanofilariasis affected cattle were treated with Trichlorphon, an organophosphorus (Neguvon ointment, Sapco Unichem, Bangladesh). Topical application of 8% Neguvon ointment (8% Neguvon plus 4% sulphanilamide plus 88% Vaseline) was given every 3 days intervals for up to 30 days. On the first day ointment applied after thorough cleaning, washing and scrubbing.

2.4.3 Group C: This group also consisted of 10 clinical cases of Stephanofilariasis which were treated with ivermectin injection SC (A-Mectin Inj. ACME, Bangladesh). A-Mectin was administered at the rate of 0.2 mg/kg bw subcutaneously and repeated after 28 days.

2.4.4 Group D: (n=10), the animals in this group were treated with sterile Vaseline and were kept as control.

2.5 Clinical parameters: Respiratory rate, heart rate, rectal temperature was recorded according to conventional methods throughout the experimental work.

2.6 Gross observations: The animals were observed daily for any untoward reaction against suture materials e.g. breakage of suture line by scratching. Any complications were also observed. Mean swelling score was categorized as (-) no, (+) as mild, ++ as moderate and +++ as severe swelling. Diameter of incision site was graded as '—' (as cured), + (4.0-5.5 cm), ++ (5.6-7.0 cm), and +++ (7.1-10.0 cm).

2.7 Statistical analysis: The data analysis was done and expressed as Mean \pm SD. Analysis of variance (ANOVA) technique was applied using computer package programme (MSTAT), and mean differences were adjudged by Duncan's Multiple Range Test (DMRT). Student's paired 't-test' was also applied for analyzing the data on healing performances, heart rate, respiratory rate and temperature.

3. Results

3.1 Clinical parameters: The heart rate, respiratory rate and rectal temperature were observed on different experimental days. There were significant ($P < 0.05$) increase in heart rate and respiratory rate and rectal temperature at 1st hour after surgery in group A. The baseline values of heart rate, respiratory rate and temperature were 69.00 ± 1.70 , 29.90 ± 1.66 and 101.93 ± 0.59 , respectively. These values of heart rate, respiratory rate and rectal temperature increased to 71.40 ± 1.65 , 31.60 ± 0.97 and 102.73 ± 0.42 , respectively. In other groups, the variations were not significant.

3.2 Histopathology of hampsores lesions: At the centre of the lesions complete destruction and discontinuation of the epidermal epithelial layers were found. Epidermis close to the centre was hyperplastic and showed finger like projections forming reticulate pegs extending deep into the dermis. Hyperkeratosis and parakeratosis were also observed. Extensive edema, hemorrhage and leukocytes infiltration (mainly eosinophils) were detected. In the deeper layer of dermis there were newly formed capillaries. Lesions showed large numbers of ovoviviparous eggs were present at the dermis. Phenomenon of phagocytosis of the ova by eosinophils and macrophages were clearly seen. Cystic hyperplasia of the hair follicles was common histological change. The intensity of tissue reaction gradually reduced from the centre to the periphery of the lesion. Stephanofilarial parasites (Fig. 1) were usually located not at the centre of the lesions but at the periphery. In all biopsies examined the parasite was located at sites between the epidermis and dermis.

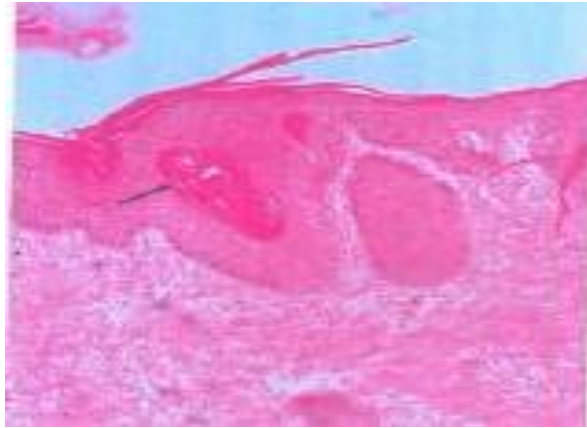


Fig.1: photomicrograph of skin in a cow infected with Stephanofilariasis (before treatment) showing presence of Stephanofilaria parasite (Arrow) in coiled form within the epidermal epithelium and huge infiltration of eosinophils. H&E X 10.

3.3 Surgical intervention of humpsores: The cattle of group A treated surgically showed 100% recovery within 10-15 days after surgery (Table 1). Three days postoperatively, the gross morphological observation of the lesions became less exudative and the size of the lesion was reduced slowly. Alopecic region of the lesions turned into smooth and growth of hairs were also seen from 25 days onward in all the animals. On histopathology, the microscopic changes appeared of enhanced healing and growth of fibroelastic tissue and controlled angiogenesis (Fig. 2).

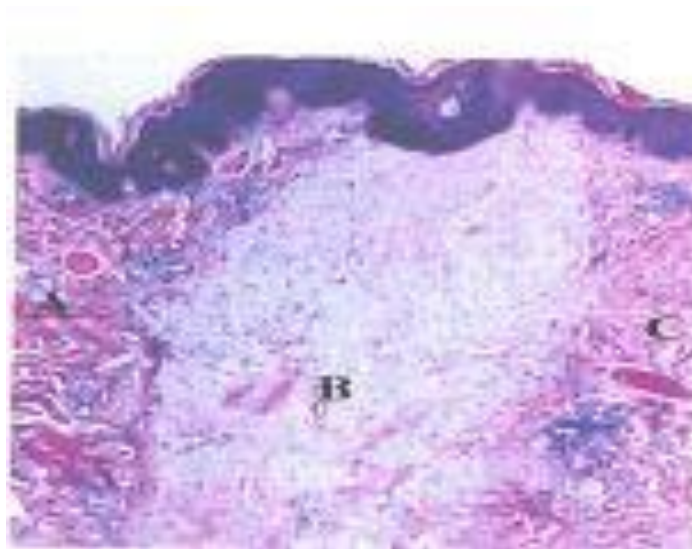


Fig. 2: Photomicrograph of a healed skin of cattle after surgical excision to a lesion caused by Stephanofilariasis showing A. Loss of cellularity. B. Fibroelastic tissue forming scar. C. controlled angiogenesis. H&E X10.

Table 1: Efficacy of different treatment methods on diameter of lesions caused by Stephanofilariasis.

| Methods | Pretreatment (diameter of lesion) in cm | Diameter of lesions (cm) at different post-treatment days | | | | | | |
|---|---|---|---------------|----------------------------|----------------------------|----------------------------|---------------|---------------|
| | | 2 | 5 | 10 | 15 | 20 | 25 | 30 |
| Surgical Excision (Group- A) | 6.80 | 6.44± 1.92 | 5.75± 1.61 | 4.46± 1.28 ^b | 2.49± 0.78 ^b | 1.67± 0.16 ^b | -- | -- |
| Organophosphorus Application (Group- B) | 6.06 | 6.06± 1.22 | 6.06± 1.22 | 6.06± 1.22 ^a | 6.01± 1.23 ^a | 5.83± 1.30 ^a | 5.35± 1.58 | 5.06± 1.76 |
| Ivermectin Injection (Group-C) | 6.07 | 6.07± 0.72 | 6.07± 0.72 | 6.07± 0.72 ^a | 5.68± 0.88 ^a | 5.44± 1.00 ^a | 5.19± 1.12 | 4.78± 1.45 |
| Control (Group-D) | 5.80 | 5.80± 1.34 | 5.82± 1.35 | 5.84± 1.35 ^a | 5.84± 1.35 ^a | 5.84± 1.35 ^a | 5.88± 1.34 | 5.88± 1.34 |
| Level of Significance | ND | NS | NS | ** | ** | ** | NS | NS |

**Significance at 1% level, NS=Not significant, ND=Not done

Figures with dissimilar letter differ significantly.

3.4 Treatment with organophosphorus ointment: Immediately following the application of the ointment the lesion become less exudative. Fly infestation was greatly reduced. The size of the lesion was reduced slowly and the rough and rugged surface of the lesion caused by scabs turned considerably smooth after fifteen (15) to twenty (20) days. Irritation and itching were also diminished. Depending on the sizes, the lesions healed up within the period mentioned above. In most of the animals the centre of the lesion was represented by soft and whitish areas.

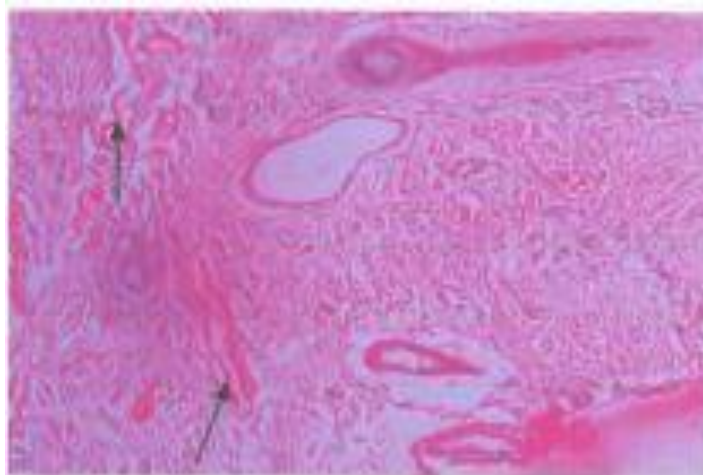


Fig.3: Photomicrograph of skin in cattle infected with *Stephanofilaria* parasite fifteen days after treatment with Neguvon ointment. Arrows indicates the presence of microfilaria of *Stephanofilaria* species in the dermis soft tissue. H&E X 40.

3.5 Treatment with ivermectin: Ivermectin injection showed 70% recovery where healing started within 15-20 days of post-treatment. Following 5 days of administration, the lesion become less exudative. Size of the lesion was reduced slowly, irritation / itching were diminished. Both the periphery and centre of the lesion turned into healing process (Fig. 3). From 15 days onward, in most animals the granulomatous ulcerative dermal lesion healed completely. In 30% animals, the wound turned to sore and animal again habited to scratch their wound from 15 days to onward of the 2nd injection.

3.6 Comparative efficacy: Effects on 5th days post treatment: The diameter of lesions was insignificantly affected by different treatment at 5th days of post-treatment. The highest healing rate of lesions even observed in surgical excision compared to the pretreatment lesions. Lowest heal was obtained in control group. At 10th days of post treatment the total number of healing of lesions in diameter was significantly ($P < 0.01$) influenced by the surgical treatment method compare to control group. Total diameter of healing of lesions decreased with increasing the days. In surgical treatment methods at day 15, the total diameter of lesions was significantly ($P < 0.01$) decreased compared to all other treatments and control groups (Table 2).

3.7 Success or failure of the different treatment: In the animals of group A (n=10) skin excision were succeeded in 10 animals. In group B (n=10) organophosphorus treatment were succeeded in 6 animals and failed in 4 animals. Ivermectin (group c, n=10) were shown succeeded in 7 animals and failed in 3 animals. In control group D failure to recovery was shown in almost all animals (Table 2).

Table 2: Response of different treatments regimens in the experimental groups.

| Groups | Duration of treatment | Time required for clinical cure | No of animals cured | % of success |
|---------------------------------------|--|---------------------------------|---------------------|--------------|
| A, (surgical excision) n=10 | 10-15 days | 15-20 | 10 | 100 |
| B, Organophosphorus application, n=10 | 30 days | 45 | 6 | 60 |
| C Ivermectin Injection, n=10 | 2 times injected, 2 nd one after 21 days of 1 st one | 45 | 7 | 70 |
| D, Control, Vaseline application | 30 days | 00 | 00 | 00 |

4. Discussion

Marked inflammation and swelling at excision site developed in almost all cases at 1st day but later decreased gradually and disappeared after 20th day of operation (group A). This is due to normal inflammatory reaction after incision. However, a moderate swelling was observed 5 to 10 days in most of the cases (Hossain, 2009). Surgical excision of the lesion revealed 100% recovery within 20 days with new growth of hairs surrounding to the incision site and no exudates, no alopecia even after 45 days of operation represents the merit of surgical incision. Histopathology of skin biopsies from the cured area of hump sore treated by 8% organophosphorus (Neguvon) ointment and Ivermectin (A-mectin) injection revealed some unsatisfactory results which may be taken into account. Even the eggs of *Stephanofilaria* parasites were found in unhealed skin section. Although complete healing of the damaged epidermis took place, no restoration of the damaged hair follicles and adnexal structures of the skin were noticed at the newly healed up areas which is corresponded with the report (Baki and Dewan, 1975). However, the observation in this study may have been too early to predict complete restoration of the histological structures in the newly healed sore. Conversely, histopathology of skin biopsies from healed up areas after surgical incision revealed the restoration of the surrounding hair follicles and adnexal structure. Also, in these biopsies at the dermis we found hyperplasia of the endothelial cells with no skin appendages and increased production of new capillaries around the scar tissue, which is a good indication of normal supply of blood to the newly cured region. It was also found that ivermectin treatment was more effective in comparison to organophosphorus application considering the time required for and number of healing. However, surgical excision revealed complete healing in shortest time where the rate of healing was also 100%. Roy and Misra (1991) recorded topical application of 1% ivermectin ointment, 0.5% ivermectin ointment also effective for the treatment, assessed after 6 months was 80% and 50%, respectively. In Wikipedia (2009), it was mentioned that the lesion occurs in Asia and is caused by *Stephanofilaria* species and that ivermectin is efficient for individual treatment of the illness. But surgical excision, although very hemorrhagic, is far more efficient. Moreover, our findings also correspond to a previous study (Agarwal and Shah, 1984). In this study it was

evident that topical application of 8% organophosphorus (Neguvon) ointment is less effective which is in accord with the study reported (Baki and Hossain, 1984). They found the centre of the lesion remained active although the size of the lesion reduced considerably. Even in healed cases the centre of the lesion remained hair less and again fly infestation was recorded. On the basis of parasite counts in skin scraping's, ivermectin was effective as a microfilaricide but removal of adults was incomplete and constant re-infection meant that meaningful interpretations were not possible which was correlated with (Gill et al. 1991). Rahman et al. (2009) found that the ivermectin was therapeutically effective against skin lesions (Scabies, humpsore and wounds) in calves and goats.

5. Conclusions

Surgical intervention is the best treatment for Stephanofilariasis in cattle. Complete recovery of the lesion was shown in surgical intervention group then in ivermectin injection group then organophosphorus application group which was proved even by histopathologically.

Considering the rate and time of healing of the lesion surgical excision of affected skin is more effective than organophosphorus application and ivermectin injection for maintaining normal patency of skin.

References

- Agrawal MC and Shah HL (1984). Stephanofilarial dermatitis in India. *Vet Res Communic* 8:93-102. Publisher Elsevier Scientific, Amsterdam, Netherlands
- Baki MA (1995). Experimental transmission and pathology of humpsore (Stephanofilariasis) in cattle. PhD thesis, Department of pathology, Bangladesh Agricultural University (BAU), Mymensingh 2202, Bangladesh.
- Baki MA and Dewan ML (1975). Evaluation of treatment of stephanofilariasis (humpsore) with Neguvon (Bayer) by clinicopathological studies. *Bang Vet J* 9:1-6
- Baki MA and Hossain MA (1984). Neguvon against humpsore in cattle. *The Bang Veterinarian* 1:14-16
- Gill BS, Balakrishnan P, Lumsden GG and Jones PGH (1991). Treatment of stephanofilariasis (Earsore) with ivermectin. *Vet Parasitol* 40(1-2): 159-163.
- Hossain MA (2009). An experimental study on perineal urethrostomy in goats. MS in Surgery. Thesis, Department of Surgery and Obstetrics, Bangladesh Agricultural University.
- Phukan SC, Das M and Barkakoty MR (2005). Humpsore in cattle in Assam. *J Vet Parasitol* 19(1):35-37.
- Rahman MM, Mostofa M, Jahan MS and Kamal MAHM (2009). Comparative efficacy of Neem leaves and ivermectin (Ivomec) against ectoparasites in calves. *BAU J* 7(1):73-78.
- Roy S and Misra SK (1991). A note on efficacy of ivermectin and levamisole topically against Stephanofilarial dermatitis. *Indian J Vet Med* 11:72-73.
- Stulberg D and Penrod M (2002). Caring for common skin conditions: Common bacterial skin Infection. *Am Family Physician* 66:119-124.

Wikipedia (2009). Verminous haemorrhagic dermatitis (cattle). From Wikipedia, the free Encyclopedia.