



## Investigation on the prevalence and pathology of subclinical paratuberculosis (johne's disease) in apparently healthy One Humped Camels (*Camelus Dromedarius*) in Jordan

W. M. Hananeh<sup>1</sup>, D.V.M., MSc., DACVP., N. Q. Hailat<sup>1</sup>  
D.V.M., Ph.D., H.S. Hemida<sup>1</sup>, D.V.M., MSc., J. R. Stabel<sup>2</sup>

<sup>1</sup> Department of Pathology and Animal Health, Faculty of Veterinary Medicine, University of Science and Technology, Irbid-Jordan and <sup>2</sup> National Animal Disease Center, USDA-ARS 2300 Dayton Road, Ames, IA 50010  
whananeh@just.edu.jo

### Article Info

Received:12.05.2013  
Accepted:25.05.2013  
Published online:01.06.2013

ISSN: 2231-9123

© 2012 Design for Scientific Renaissance All rights reserved

### ABSTRACT

Paratuberculosis (Johne's disease) (JD) is infectious, chronically progressive granulomatous enteritis affects domestic and exotic ruminants including camels. The causative agent is *Mycobacterium Avium Paratuberculosis* (MAP), a slow growing mycobactin-dependent acid-fast bacillus. We investigated the occurrence of Johne's disease in apparently healthy camels, using 100 tissue samples, 50 ileum and 50 corresponding mesenteric lymph nodes, by histopathological, immunohistochemical (IHC) and Acid-fast stain examination. The prevalence of JD in camels in our study was 32% and 34% using histopathology and IHC respectively. Grading from I-IV of histopathological lesions based on type of cellular infiltrate and severity of lesions, where grade I has mild lesion and grade IV has very severe lesion. Most of the positive cases were in grades I and II. Furthermore staging I-III of IHC results using a polyclonal rabbit antibody specific to MAP, has presented a high number of positive cases in stage I. Statistical analysis of these results showed a significant correlation between histopathology and IHC. These results showed that histopathology and IHC revealed the occurrence of paratuberculosis in apparently healthy camels in Jordan. It is interesting to note that this is the first study of JD in camel in Jordan and the results strongly suggest alarming fears of severity of the disease at the national level.

**Keywords:** Camel, *Camelus dromedarius*, histopathology, ileum, immunohistochemistry, paratuberculosis, prevalence, Jordan.

## 1. Introduction

Johne's disease (JD) is infectious, incurable, chronically progressive granulomatous enteritis affects domestic and exotic ruminant (Coetsier et al. 1988). The causative agent is *Mycobacterium avium paratuberculosis* (MAP), a facultative intracellular acid-fast bacillus. MAP is an extremely slowly growing mycobactin-dependent organism that replicates within macrophages of both the gastrointestinal tract and associated lymphoid tissues (Chiodini et al.1984; Klausen et al. 2003). JD progresses through several stages and, in the majority of cases take several years from infection to manifest clinical signs. Buergelt et al. (1978) showed that infected animals pass through three main disease stages classified as: (i) subclinical, non-shedding; (ii) subclinical, shedding; (iii) clinical and intermittently or permanently shedding. Each of the stages is marked by specific pathologic changes which are best recognized at the microscopic level (Collins et al. 2000). Buergelt et al. (2000) suggested that there is no challenge for the pathologist to detect the clinical JD; however, subclinical disease is difficult. Very limited studies on JD have been conducted in the Middle East and North African countries. Very recently, JD was reported in cattle from Egypt, in sheep in Morocco and sheep, goat, cattle and camel in Saudi Arabia (Al Hajri and Alluwaimi. 2007; Benazzi et al. 1995; Mahmoud et al. 2002; Salem et al. 2005). In Jordan, we conducted a study on apparently healthy sheep and goats using histopathological, IHC examinations, AF staining and culture (Hailat et al. 2010). We found that the disease is very prevalent (Hailat et al. 2010). We also conducted a study on apparently healthy cattle using histopathological, IHC examinations and AF staining. We found that the disease is also very prevalent in cattle (Hailat et al. 2011). Therefore, this investigation was conducted to study the occurrence of JD in apparently healthy camels using histopathology, IHC, and AF staining, as only very few investigations have been conducted on camels worldwide.

## 2. Materials & Method

- 2.1. Animals: During a period of 2 months, August to October 2004, a total of 47 camels, slaughtered at the regional slaughter house were used in this study. Before culling, information was obtained concerning animal's age, sex, and health status. Clinical signs were also recorded.
- 2.2. Gross examination and tissue sampling: After slaughter, complete gross examination was performed with emphasis on the digestive system (small and large intestines) and regional lymph nodes. Information about corrugation, thickening and hyperemia of the intestine were recorded. Furthermore, lymph node size, shape and color were also reported. Any other significant gross pathological findings were also recorded. Intestinal (ileum) and the corresponding lymph node samples were collected and fixed in 10% buffered formalin for further examinations.
- 2.3. Histopathological Examination: The formalin-fixed tissue samples were processed by routine methods. Sections (4-5µm) were cut and stained with haematoxylin and eosin

(H&E). Sections were examined histopathologically. Lesions were classified into four grading groups I, II, III and VI / special grade, according to the type and amount of cellular infiltration. The grading criteria of tissue lesions that were used are shown in Table (1).

**Table 1:** Histopathological criteria for grading of the lesions found in the last part of the ileum and the ileo-cecal valve and respective lymph nodes.

Finding	Grade
A- Absent or very few macrophages and lymphocytes without apparent thickening of the intestinal mucosa	Negative
	+1
B- Many lymphocytes with some Macrophages with occasional or no epithelioid cells.	
C- In addition to the previous criteria, presence of many macrophages with an increased number of lymphocytes and few scattered epithelioid cells.	+2
	+3
D- In addition to criteria of previous grade, observation of a prominent number of epithelioid cells in nests or scattered.	
	Special(SP)
E- Presence of multinucleated giant cells with or without epithelioid cells within typical granulomatous lesion.	

Immunohistochemistry: Tissue sections (3µm) were placed on vectabond (DAKO A/S, Glostrup, Denmark) coated slides. The tissue samples, from paraffin-wax embedded blocks, were sectioned in 2-3 µ laid on vectabond coated slides, dried by air and then allowed in oven at 55°C for 2 hours. Tissue sections were deparaffinized hydrated by sequential immersion of slides in graded concentration of ethanol (100%, 95% and 70%) for one minute each. then washed in distilled water for 5 minutes. After being washed in PBS, the tissue sections were immersed in citrate buffer solution pH=6, 10mM and antigen retrieval was carried out by autoclaving the tissue section at 120°C in 15 psi for 15 minutes (Express, Italy). Endogenous peroxidases were inactivated by immersion of the slides in a solution of 15% hydrogen peroxide - methanol for 30 minutes. Non-specific adherence of proteins to tissue sections was blocked using 1% bovine serum albumin (BSA), (Sigma Chemical Co., PO. Box14508, St.Louis, MO63178) incubated for 2 hrs. The solution was drained from the slides and the polyclonal *M. paratuberculosis* antiserum, raised in rabbit diluted 1:500 in PBS was applied for 2hrs. Universal biotinylated anti-goat, anti-rabbit, and anti-mouse immunoglobulin (DAKO A/S, Glostrup, Denmark) diluted at 1:20 was applied as secondary antibody, and the slides were incubated for 15 minutes. After washing, Strept-Avidin biotin complex peroxidases (DAKO, A/S, and Glostrup, Denmark) was applied, and incubated on the tissue section for 15 minutes. The slides were washed and were exposed to chromogen 3, 3

diamino-benzidin-4HCL (DAB, electron microscopic product, DAKO) 1mg /ml in PBS supplemented with hydrogen peroxide (10  $\mu$ l of 3% hydrogen peroxide for 2ml of DAB) and incubated at room temperature for 3- 5 minutes. The slides were washed in distilled water for 5 minutes followed by counter staining in haematoxylin 2-3 minutes and immersing in bluing water for 30 seconds. Slides were dehydrated in graded alcohol (70%, 95%, 100% three passes) one minute each and cleared in xylene (3 passes one minute each) and mounted using DPX for further observation. Slides were examined microscopically (Eclipse 800, Nikon, Japan) using 4x, 10x and 40x objectives. Sections were considered positive according to the color observation indicative of antibody antigen reaction, and manifested by intra-cytoplasmic or extra-cellular brown coloration in different areas of the stained tissue section. The findings were registered by counting the number of reactions, accordingly starting from one cell reaction (strongly brown stained macrophage) recorded as positive, and 1-10 as 1+, more than 10 reactions, as 2++, reaction in 50% or more cells from one field was graded as 3+++ . Additionally, the intensity of the reaction was considered and in all cases only strong brown color was recorded as positive reaction. In all cases positive and negative control slides were processed together from the same known group of tissue sections, in order to avoid false positive and negative reaction. The rabbit antibody was kindly provided by Dr. Stabel from the National Animal Disease Center, Ames, AI, USA. IHC examination was performed on both intestine and associated mesenteric lymph nodes.

### 3. Results

Gross examination of camel intestinal segments, mainly ileum, showed 6 cases out of 47 had variably thickened mucosae. In one case the lumen of the examined ileal sample was obliterated with multiple variably sized up to 2cm in diameter polyps- like structure. No such lesions were observed in intestine segments other than the ileum. Three (6 %) ileal and ileo-cecal mesenteric lymph nodes were 5 times larger than those of normal counterparts and they were markedly edematous. No significant gross lesions were observed from organs other than ileum and mesenteric lymph node except for serous atrophy of fat in the emaciated animals. The histopathological lesions were variable ranging from mild to severe. In mild cases the lamina propria and submucosa of the ileum was mildly and loosely infiltrated with mononuclear cells, consisting primarily of lymphocytes with a few numbers of macrophages, plasma cells and occasional epithelioid cells. In severe cases, extensive numbers of inflammatory cell infiltrates mainly macrophages and epithelioid cells with lymphocytes and plasma cells were present throughout the intestinal layers (Fig. 1).

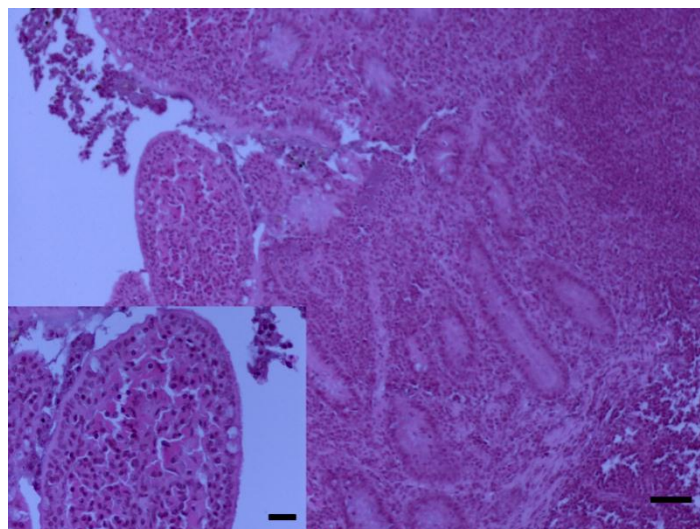


Fig. 1: Ileum- camel. The lamina propria is disrupted by large numbers of epithelioid cells. Villous atrophy is prominent. H&E stain. Bar= 50  $\mu$ . Inset: atrophied villous that is infiltrated with large numbers of epithelioid cells. H&E stain. Bar= 20  $\mu$ .

In some

cases, the epithelioid cells formed sheets of inflammatory cells. The grossly visible polyp-like structures represent extensive lymphoid follicular hyperplasia of the Gut Associated Lymphoid Tissue (GALT) (Fig. 2) intermingled with large numbers of mononuclear cell infiltrates. Less frequently, necrosis of the center of epithelioid cell aggregate was apparent (Fig. 3).

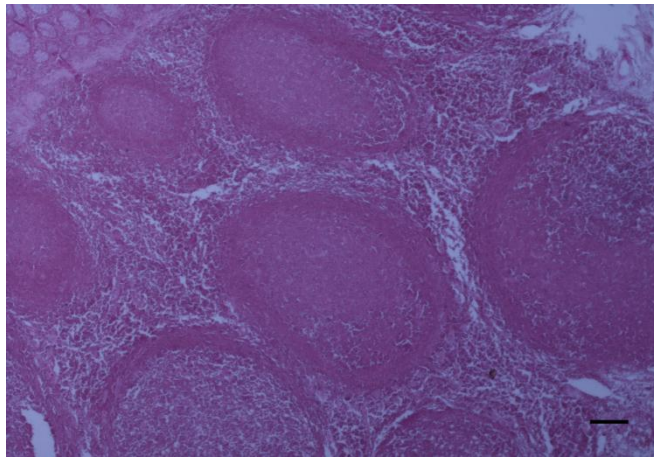


Fig. 2: Ileum-camel. The GALT is markedly hyperplastic intermingled with large numbers of mononuclear cell infiltrates. H&E stain. Bar= 50  $\mu$

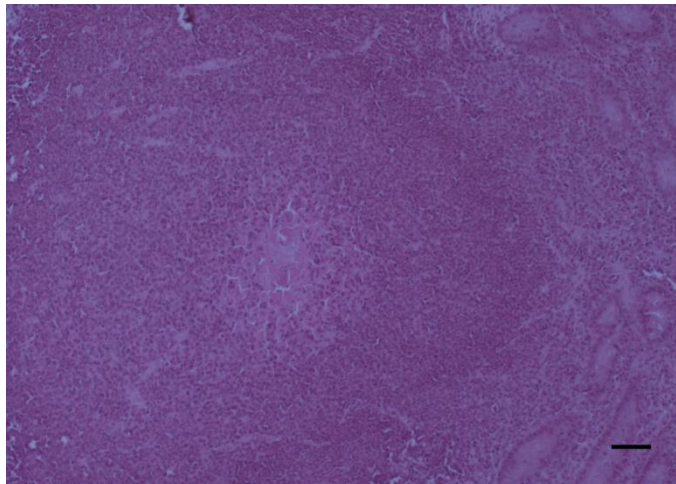


Fig. 3: Ileum, camel. The GALT is necrotic with epithelioid cell aggregate. H&E stain.  
Bar= 20  $\mu$

Other significant villous changes including; disruption of the normal architecture of the villi, villous atrophy and fusion are seen. Areas of necrosis are rarely seen in the intestinal sections. Table (2) provides a summary of the prevalence of JD in subclinical apparently healthy camels in Jordan using histopathological, and IHC examinations of the ileum. Out of 47 tissue samples, 15 (32%) had histopathological lesions consistent with JD. Furthermore, out of 47 intestinal samples examined 16 (34%) were positive using IHC (Table 2, Fig. 4). Statistical analysis of the results showed no significant difference between the prevalence of the disease using histopathological and IHC examinations. To better understand the pathogenesis of the disease in camels, the corresponding regional mesenteric lymph nodes (MLNs) were also examined by histopathological and IHC techniques (Table 2). Analysis of the results showed that out of 47 lymph nodes examined by histopathology, 8 (17%) showed granulomatous reaction with the presence of epithelioid cells, whereas by IHC, 14 (30%) were positive which are consistent with JD . There was significant difference between the histopathological and IHC examinations of the MLNs.

**Table 2:** Distribution of positive cases of intestine (ileum) and MLNs of camel examined by histopathology and IHC in Jordan.

Tissue	Histopathology			Immunohistochemistry		
	Tissue No.	Pos <sup>a</sup>	(%)	tissue No.	Pos	(%)
Ileum	47	15	32%	47	16	34%
MLNs	47	8	17%	47	14	30%

(a) POS= Positive.

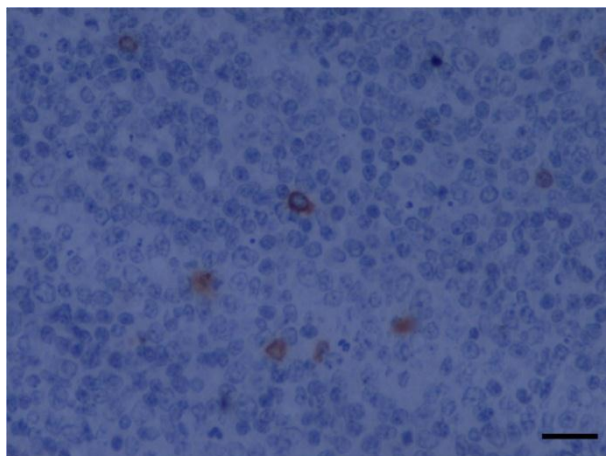


Fig. 4: Mesenteric lymph node- Camel. Scattered intense cytoplasmic anti MAP expression. IHC with haematoxylin counterstain. Bar= 20

The grade distribution of JD positive cases in camel using histopathological examination of ileum shown in Table (3). The majority of the positive cases (18%) were in grade I while no case (0%) was in grade IV.

**Table 3:** Grade distribution of JD positive cases in camel using histopathological examination of ileum in Jordan.

Tissue No.	Histopathology grades			
	I (%)	II (%)	III (%)	IV (%)
47	9 (18%)	3 (7%)	3 (7%)	0(0%)

#### 4. Discussion

Johne's disease has gained the attention of many countries in the world because of the economical losses in cattle and small ruminant industry, and its potential for transmission to human, namely Crohn's disease (El-Zaatari et al. 2001). However; very few studies were

conducted on camels. In addition, it is not known whether camels have the cattle, sheep, intermediate strain or a combination of thereof. Although the apparent prevalence of paratuberculosis or JD in camelid populations (llamas, alpacas and guanacos) is low, some reports indicated that they are at risk for infection (Kramsky et al. 2000). A recent survey study of camel diseases in Jordan has focused primarily on parasitic infestations and some bacterial and viral diseases, but no information was reported on JD (Al-Rawashdeh et al. 2000). Very limited information is available regarding the epidemiology and pathology of JD in camelids (Stehman, 1996). Identifying similarities as well as differences between cattle and camelid infection may assist veterinarians in making an accurate diagnosis (Kramsky et al. 2000). In many countries in the Middle East and North Africa, camels are raised either separately or with sheep and goats using some times the same grazing land. This type of camel husbandry increases the opportunity of contamination and transmission of the disease. Kramsky et al. 2000) reported that the sub clinically infected animal may be contaminating the premises with the organism, thus exposing susceptible herd mates to infection. Analysis of the histopathology results in this study revealed that the disease occurs in Jordan. The prevalence was 32%. Gross tissue examination revealed 6 ileum tissues presenting thickening of the mucosa and only one case showing corrugation. From North America, individual cases has been reported in llamas (*Lama glama*), and as of July 1998, 33 alpacas (*Lama pacos*) residing in Australia have been confirmed to be infected with JD (Belknap et al. 1994; Huda and Jensen.2003). Similar to cattle, camelid paratuberculosis infections may proceed undetected for a prolonged period of time (Kramsky et al. 2000). In a previous study the prevalence of JD in apparently healthy sheep in Jordan was 97% by histopathology and 93% by IHC. However, in cattle the prevalence is 65% (Hailat et al. 2011). This suggests that there is a link between the different animal species sharing the infection at raising and rearing methods. The prevalence in camels is lower than that of cattle and sheep and this could be due to the immune system and grazing habits.

In the present study we have used a polyclonal rabbit antibody specific to MAP tested and used in many published studies, they describe the production of polyclonal antisera in rabbits and demonstrate the efficacy of the antibodies in IHC detection of *M. paratuberculosis* in bovine tissue. Polyclonal antibodies to *M. paratuberculosis* preparations were raised in New Zealand White rabbits and were utilized in IHC staining of ileum and lymph node from cows infected with paratuberculosis. Similar staining intensities were present in both tissues of all animals. A serial titration of the polyclonal antisera demonstrated that the antibody had a higher binding affinity to *M. paratuberculosis*. Immunoreactivity was present in the cytoplasm of macrophages and giant cells and extracellularly. No staining was apparent in other cell types present. Antisera were evaluated for cross-reactivity with *M. bovis* antigens by IHC staining of tissues from infected animals. Prefemoral and cervical lymph nodes and liver samples obtained from pigs intravenously infected with *M. bovis* were stained with the *M. paratuberculosis* polyclonal antibodies. Tissues were devoid of positive reactivity regardless of which antiserum was used when evaluated at the same dilutions that demonstrated positivity in *M. paratuberculosis*-infected tissues. Sections of lymph nodes from a cow naturally infected with *M. bovis* were also stained with various dilutions of the polyclonal antibody, with no detectable cross-reactivity. It was concluded that the production



of a polyclonal antibody to cell wall proteins of *M. paratuberculosis* resulted in a highly sensitive, species-specific tool for the detection of paratuberculosis in tissue sections.<sup>24</sup> Analysis of the IHC results, confirms that the disease occurs in Jordan and the prevalence was 34%. This is the first report of JD in camels using Histopathological and IHC examination in apparently healthy camels. Buergelt and Ginn (2000) observed that subclinical disease diagnosis is more difficult by histopathology as lesions may be subtle and organisms may be rare. On the other hand, Kurade et al. (2004) has reported that histopathology was found to be a better indicator of paratuberculosis than bacteriology in sheep (Kurade et al. 2004). Furthermore, the spontaneous pathological lesions of paratuberculosis were reported in the North American bison (Buergelt et al. 2000). In addition, expertise and diagnostic criteria may vary between institutions (Buergelt et al. 2011). Therefore, accurate subclinical diagnosis needs more than one test to complement the histopathological diagnosis. In a previous study conducted in apparently healthy sheep and cattle, we found that histopathology was compatible with IHC where the disease was very prevalent in Jordan (Hailat et al. 2010). In our study, histopathology is demonstrated to be the best post-mortem method (when conducted in slaughter houses) for diagnosis of subclinical disease and control of JD. This is due to the advantages represented by its sensitivity compared to other techniques such as IHC as its utility correlates to relatively advanced infection stages and is dependent upon bacterial load. We have also found that histopathology was positively correlated with IHC, however, IHC is time consuming and expensive. Histopathology is cheap, accurate and most economical. When conducted by a professional and expert pathologist, histopathology could be considered a “gold standard”. This prevalence is considered high in subclinical camel in Jordan. This is may be explained by the high prevalence of the disease in sheep, goats and cattle (Hailat et al. 2011). The disease was reported in virtually every country that has agriculture and laboratory capability to diagnose the disease and countries had conducted surveys on JD to estimate the prevalence of JD in their cattle herds. Prevalence of infection in most countries in the world is unknown. In the Middle East region, JD was reported in cattle from Egypt with a prevalence of 16.7% in native cattle and 85.7% in Holstein cows reared in Egypt, and in sheep in Morocco; however, in Saudi Arabia JD was reported in sheep, goat, cattle and camel (Al Hajri and Alluwaimi. 2007; Benazzi et al. 1995; Mahmoud et al. 2002; Salem et al. 2005). However, very few studies were conducted on camels (Klausen et al. 2003). In Saudi Arabia (Al-Hizab, 2010). reported the gross and histopathological lesions of JD in three, One Humped Camels (*Camelus Dromedarius*). The author reported pathological changes similar to those occurred in sheep. In the light of these data, subclinical JD in camel in Jordan is considered to be high and more studies must be conducted on camels (Al-Hizab, 2010). Results of mesenteric lymph nodes using histopathological examination (17%) correlated neither with those obtained with intestine (ileum) (32%) nor with results of IHC examination (34%) . This could be explained by the difficulties in histological evaluation of lymph node due to the natural cell population dominated by lymphocytes which makes real evaluation of infiltration more restrictive, and also to the changes occur during disease development. We conclude that lymph node examination by histopathology is not necessary when we have ileum sections. When using IHC, results correlated to those obtained by histopathology and reflected the association between the immunological reactions and histological sequential changes (Kurade

et al. 2004; Sigurdardottir et al. 1999). IHC technique results showed the utility of this technique in detection of bacterial antigens. IHC results showed also a strong correlation between the two different tissue samples, Ileum 34% and MLNs 30% respectively (Table 2). These results are found for the first time, and these data may help in future studies giving choice in diagnostic methods by reducing time and cost of JD diagnosis. Statistical analysis also confirmed the correlation between the two techniques. Regarding to the low sensitivity of IHC and based on the present results, we conclude that histopathological examination can be used alone without IHC examination although, this technique is considered as a good diagnostic tool when associated with other immunological diagnostic methods especially of the cellular mediated type immunity (Lee et al. 2001; Stabel et al. 1996).

## 5. Conclusion

Johne's disease occurs in Jordan and reported for the first time in camels. Disease prevalence in camels is lower than that of cattle and sheep and this could be due to the immune system and grazing habits. The histopathological picture can be used alone without IHC examination for diagnostic purposes. The study indicates that lymph node examination by histopathology is not necessary when ileum histopathology sections are examined. IHC examination is considered as a good diagnostic tool when associated with other immunological diagnostic methods.

**Acknowledgment:** We thank the deanship of research at Jordan University of Science and Technology for supporting this research work.

## References

- Al Hajri, S.M., and A.M. Alluwaimi (2007). ELISA and PCR for evaluation of subclinical paratuberculosis in the Saudi dairy herds. *Veterinary Microbiology*. 121:384-385.
- Al-Hizab, F.A. (2010). Johne's disease in One Humped Camels (*Camelus Dromedarius*) in Saudi Arabia. *Journal of Camel Practice and Research*, 17, 31-34
- Al-Rawashdeh, O.F., F.K. Al-Ani, L.A. Sharrif, K.M. Al-Qudah, Y. Al-Hami, and N. Frank. (2000). A survey of camel (*Camelus Dromedarius*) diseases in Jordan. *Journal of Zoo and Wildlife Medicine*. 31:335-338.
- Belknap, E.B., D.M. Getzy, L.W. Johnson, R.P. Ellis, G.L. Thompson, and W.P. Shulaw.(1994). Mycobacterium paratuberculosis infection in two llamas. *J. Am. Vet. Med. Assoc.* 204:1805-1808.
- Benazzi, S., J. Berrada and T. Schliesser. (1995). First report of paratuberculosis (Johne's disease) in sheep in Morocco. *Zentralbl Veterinarmed. B.* 42:339-344.
- Buergelt, C.D., A.W. Layton, P.E. Ginn, M. Taylor, J.M. King, P.L. Habecker, E. Mauldin, R. Whitlock, C.Rossiter, and M.T. Collins. (2000). The pathology of spontaneous paratuberculosis in the North American Bison (*Bison Bison*). *Vet. Pathol.* 37:428-438.
- Buergelt, C.D., and P.E. Ginn.(2000). The histopathologic diagnosis of subclinical Johne's disease in North American bison (*Bison bison*). *Vet. Microbiol.* 77:325-331.

- Buergelt, C.D., C. Hall, K. McEntee, and J.R. Duncan.1978. Pathological evaluation of paratuberculosis in naturally infected cattle. *Vet. Pathol.* 15:196-207.
- Chiodini, R.J., H.J. Van Kruiningen, and R.S. Merkal.(1984). Ruminant paratuberculosis (Johne's disease): the current status and future prospects. *Cornell Vet.* 74:218-262.
- Coetsier, C., X. Havaux , F. Mattelard, S. Sadatte, F. Cormont, K.Buergelt, B. Limbourg, D. Latinne, H.Bazin, J.F. Deneff, and C. Cocito.(1998). Detection of *Mycobacterium avium* subsp. paratuberculosis in Infected Tissues by New Species-Specific Immunohistological Procedures. *Clinical and Diagnostic Laboratory Immunology.* 5:446-451.
- Collins, M.T., G. Lisby, C. Moser, D.Chicks, S. Christensen, M. Reichelderfer, N. Hoiby, B.A. Harms, O.O. Thomsen, U. Skibsted, and V. Binder. (2000). Results of Multiple Diagnostic Tests for *Mycobacterium avium* subsp. paratuberculosis in Patients with Inflammatory Bowel Disease and in Controls. *Journal of Clinical Microbiology.* 38:4373-4381.
- El-Zaatari, F. A. K., M. S. Osato, and D. Y. Graham. (2001). Etiology of Crohn's disease: the role of *Mycobacterium avium* paratuberculosis. *Trends Mol. Med.* 7:247-252.
- Hailat, N. Hananeh, W. Metekia, A. Al-Majali, A. Stabel, J. and Lafi, L. (2010). Pathology of Subclinical Paratuberculosis (Johne's Disease) in Awassi Sheep with Special Reference to its Occurrence in Jordan. *Veterinari Medicina*, 55, (10): 590-602
- Hailat, N. Hemida, H. Hananeh, W. Stabel, J. Rezig, F. Jaradat, S and Al-Saleh, A.(2011). Investigation on the occurrence and pathology of paratuberculosis (Johne's disease) in apparently healthy cattle in Jordan *Comp Clin Pathol.* (2011): 1-10, March 01, 2011
- Harkin, J.T. (1998). Johne's disease and Australian camelids. In: *Proceedings of the Australian Camelid Veterinary Association, Australian Veterinary Association Annual Conference, Sydney, Australia.*
- Huda, A., and H.E.Jensen.(2003). Comparison of histopathology, cultivation of tissues and rectal contents, and interferon-gamma and serum antibody responses for the diagnosis of bovine paratuberculosis. *J. Comp. Pathol.* 129:259-267.
- Klausen, J., A. Huda, L. Ekeroth, and P.Ahrens.(2003). Evaluation of serum and milk ELISAs for paratuberculosis in Danish dairy cattle. *Prev. Vet. Med.* 58:171-178.
- Kramsky, J.A., D.S. Miller, A.Hope, and M.T.Collins.(2000). Modification of a bovine ELISA to detect camelid antibodies to *Mycobacterium paratuberculosis*. *Vet. Microbiol.* 77: 333-337.
- Kurade, N.P., B.N. Tripathi, K. Rajukumar, and N.S.Parihar. (2004). Sequential Development of Histologic Lesions and Their Relationship with Bacterial Isolation, Fecal Shedding, and Immune Responses during Progressive Stages of Experimental Infection of Lambs with *Mycobacterium avium* subsp. paratuberculosis. *Vet. Pathol.* 41:378-387.
- Lee, H., J.R. Stabel, and M.E. Kehrli.(2001). Cytokine gene expression in ileal tissues of cattle infected with *Mycobacterium paratuberculosis*. *Vet. Immunol. Immunopathol.* 82:73-85.
- Mahmoud, O.M., E.M. Haroun, M.G. Elfaki, and B. Abbas.(2002). Pigmented Paratuberculosis granulomata in the liver of sheep. *Small Ruminant Research.* 43:211-217.
- Salem, M., A.A. Zeid, D.Hassan, A. El-Sayed, and M.Zschoeck. (2005). Studies on Johne's disease in Egyptian cattle. *J. Vet. Med. B. Infect. Dis. Vet. Public Health.* 52:134-137.

- Sigurdardottir, O.G., C.M. Press, F. Saxegaard, and O. Evensen. (1999). Bacterial isolation, immunological response, and histopathological lesions during the early subclinical phase of experimental infection of goat kids with *Mycobacterium avium* subsp. paratuberculosis. *Vet. Pathol.* 36:542-550.
- Stabel, J.R., M.R. Ackermann, and J.P.Goff. (1996). Comparison of polyclonal antibodies to three different preparations of *Mycobacterium paratuberculosis* in immunohistochemical diagnosis of Johne's disease in cattle. *J. Vet. Diagn. Invest.* 8:469-473.
- Stabel, J.R., S.J. Wells, and B.A. Wagner. (2002). Relationships between Fecal Culture, ELISA, and Bulk Tank Milk Test Results for Johne's Disease in US Dairy Herds. *J. Dairy. Sci.* 85:525-531.
- Stelman, S.M. (1996). Paratuberculosis in small ruminants, deer, and South American camelids. In: Sweeney, R.W. (ed.). *The Veterinary Clinics of North America: Food Animal Practice*, Saunders, Philadelphia, PA, Pp. 441-455.